



PRESENTING CLINICAL SIGNS

History: Presented for 1-2 day history of paraparesis. Possible spinal problem. Pre-steroid cardiac evaluation.

DATE

3/30/23

ECHOCARDIOGRAPHIC FINDINGS

2D, M-mode, and Doppler study.

PERFORMED BY:

Kelly Vazquez

Left atrial size is normal. The mitral valve appears normal, though trace mitral regurgitation is present. Left ventricular wall thickness is normal. Left ventricular internal dimensions are normal. Left ventricular systolic function is hyperdynamic. The aorta and aortic valve are normal. Right atrial and right ventricular dimensions are normal. The tricuspid valve is normal. The pulmonary artery and pulmonic valve are normal. No shunting lesions are visualized. No heartworms are visualized. No pericardial effusion or cardiac masses are seen.

INTERPRETED BY

Keith Blass, DVM,
MS, DACVIM
(Cardiology)

LA/Ao - 1.34
IVSd - 4.1 mm
LVPWd - 4.1 mm
LVIDd - 15.2 mm
LVIDs - 6.2 mm
FS - 59%
LVOT - 1.02 m/s
RVOT - 0.70 m/s

PATIENT

Brian Halliburton

SPECIES

Feline

ASSESSMENT/RECOMMENDATIONS

Normal echocardiogram

This examination demonstrates no evidence of structural heart disease, as trace mitral regurgitation can be considered a normal physiologic variant. As such, no reason for Brian's paraparesis is appreciated in the image set, nor is any contraindication to steroid therapy seen.

BREED

DSH

No therapy is recommended based on this exam.

SEX

A recheck echocardiogram is recommended if new physical exam and/or clinical abnormalities suggestive of the presence of cardiac dysfunction develop.

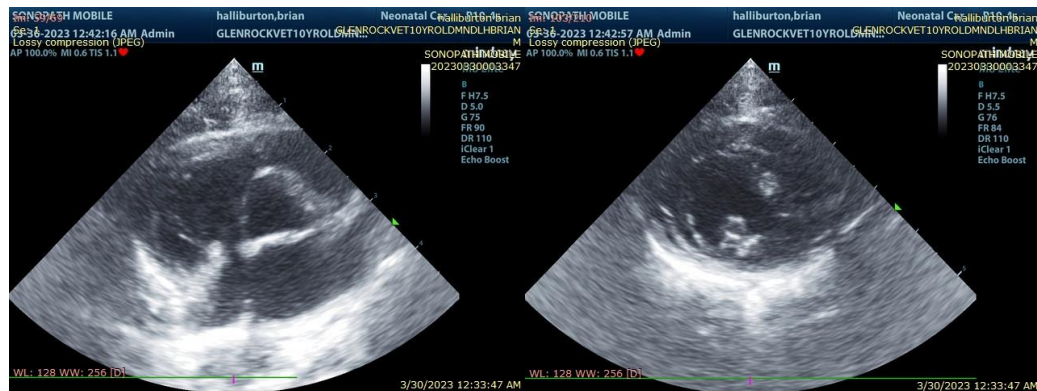
MN

AGE

>10 y

WEIGHT

11.75 lb



HOSPITAL NAME

Glen Rock VH

The information and recommendations provided are based on the images presented by the referring veterinarian. No evaluation can be communicated regarding pathology that was not visible in the image/video clips provided.

REFERRING VET

Dr. Stekler



Thank you for this referral. If the clinical or image interpretation does not parallel your findings or if I can be of any further assistance please contact me.

DATE

3/30/23 **Keith Blass, DVM, MS, DACVIM (Cardiology)**
KeithBlass@gmail.com
631-804-5754

PERFORMED BY:

Kelly Vazquez

INTERPRETED BY

Keith Blass, DVM,
MS, DACVIM
(Cardiology)

PATIENT

Brian Halliburton

SPECIES

Feline

BREED

DSH

SEX

MN

AGE

>10 y

WEIGHT

11.75 lb

HOSPITAL NAME

Glen Rock VH

REFERRING VET

Dr. Stekler